

THE NERVOUS SYSTEM

Dr. Zeina MALEK

Nervous system: Three Basic Functions

Sensory Functions: Sensory receptors detect both internal and external stimuli.

Functional unit: Sensory or Afferent Neurons

Integrative Functions: CNS integrates sensory input and makes decisions regarding appropriate responses

Functional Unit: Interneurons

Motor Functions: Response to integration decisions.

Functional Unit: Motor or Efferent Neurons



**Stimulus
(input)**

Response (output)

**Skeletal
muscle**

**Cardiac muscle,
smooth muscle,
and glands**

PNS
Sensory
receptors,
nerves,
ganglia,
and plexuses

Sensory division
conducts action
potentials
from the
periphery

Somatic
nervous
system

Autonomic
nervous
system

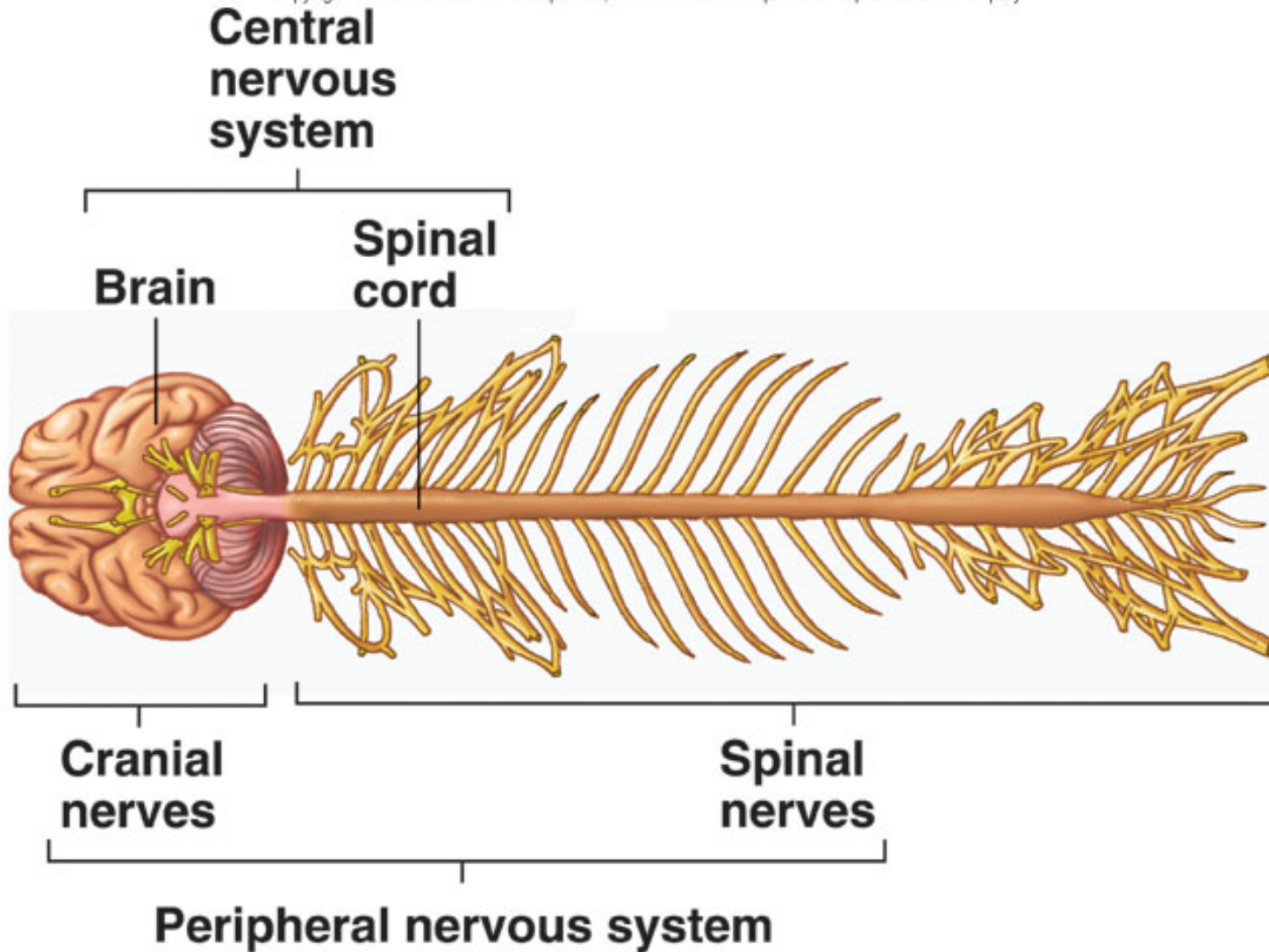
Motor division
conducts action potentials
to the periphery

CNS
Brain and
spinal cord

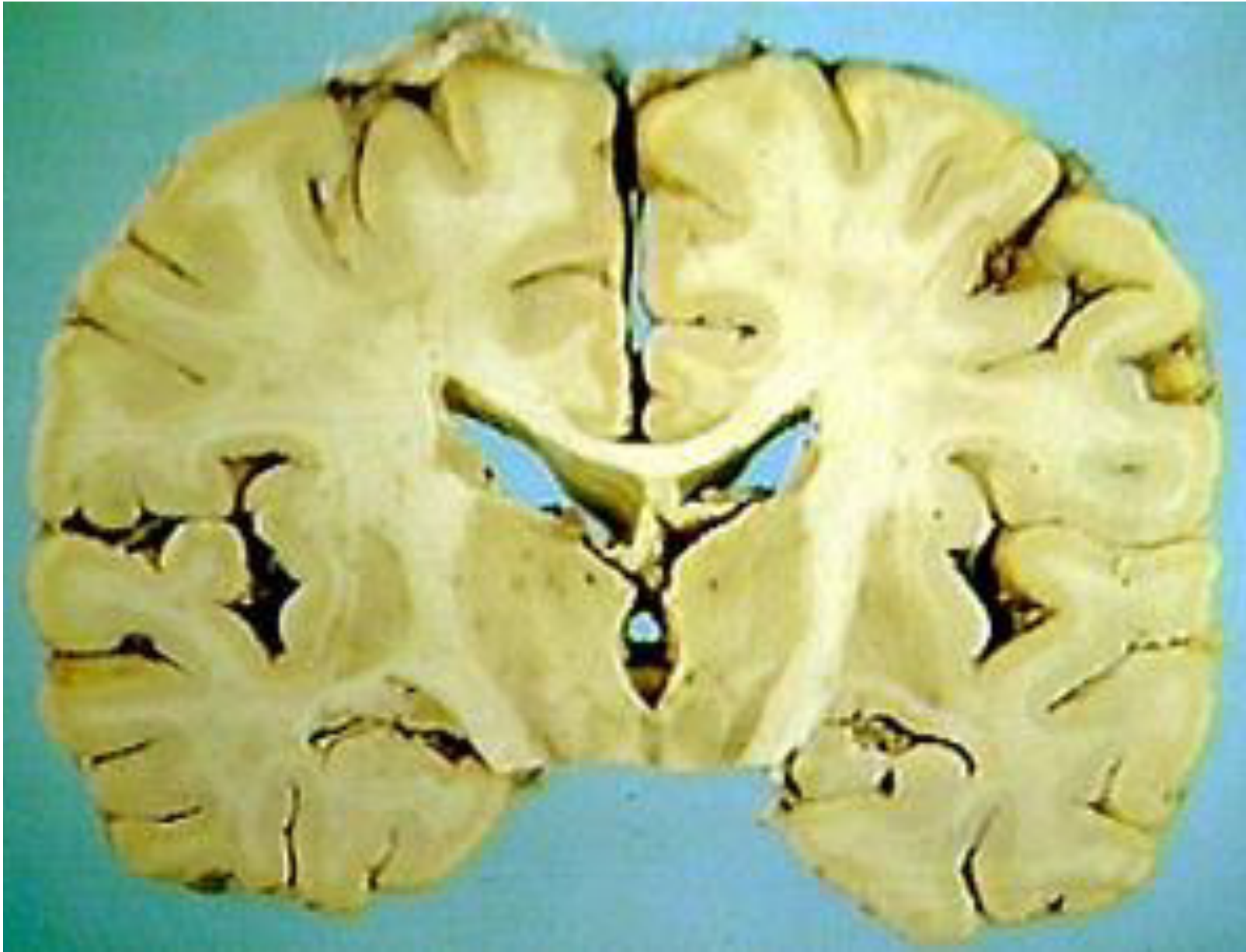Processing and
integrating information,
initiates responses, mental activity

Central Nervous System

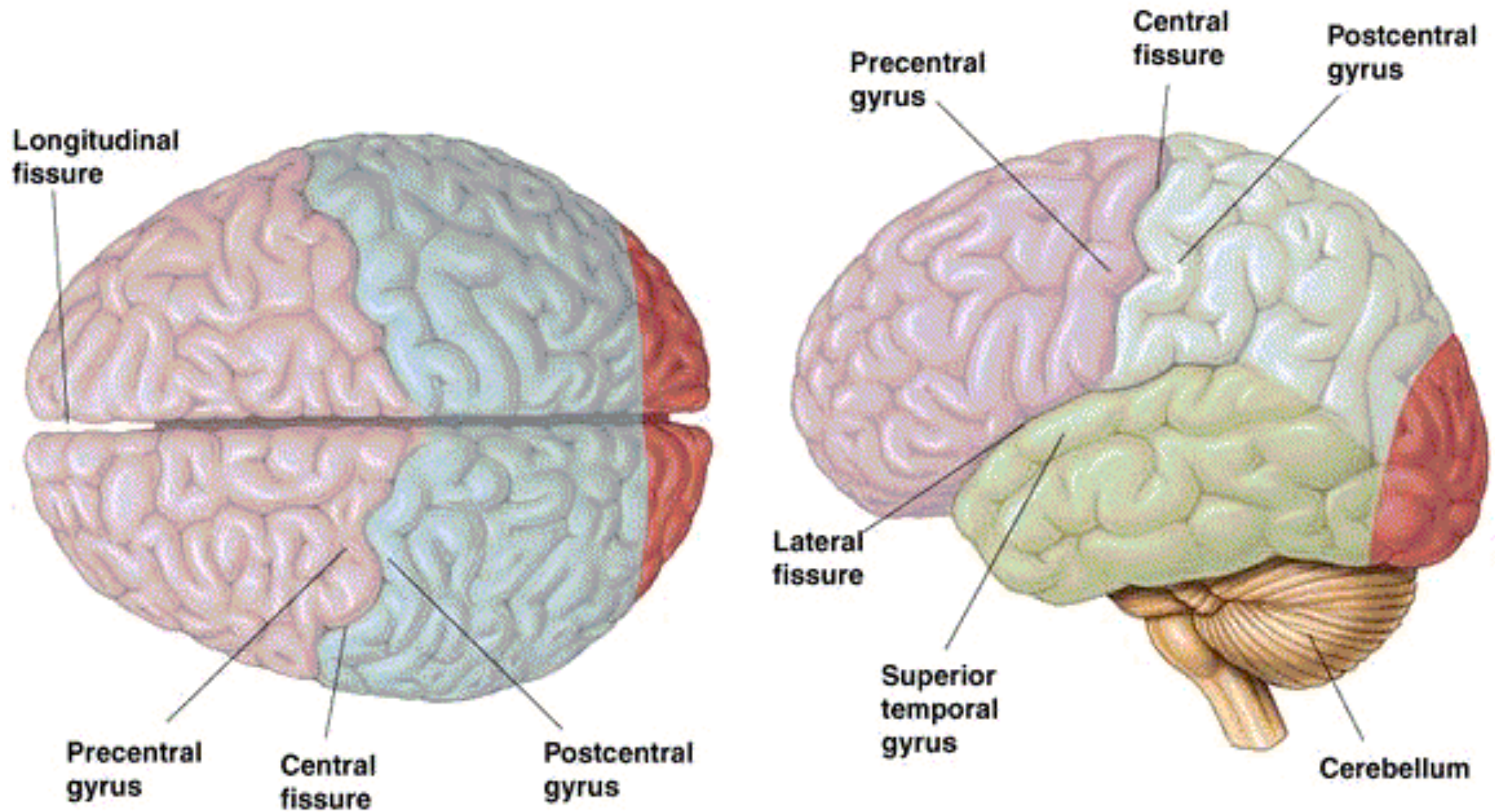
Copyright © The McGraw-Hill Companies, Inc. Permission required for reproduction or display.



Gray and White Matter

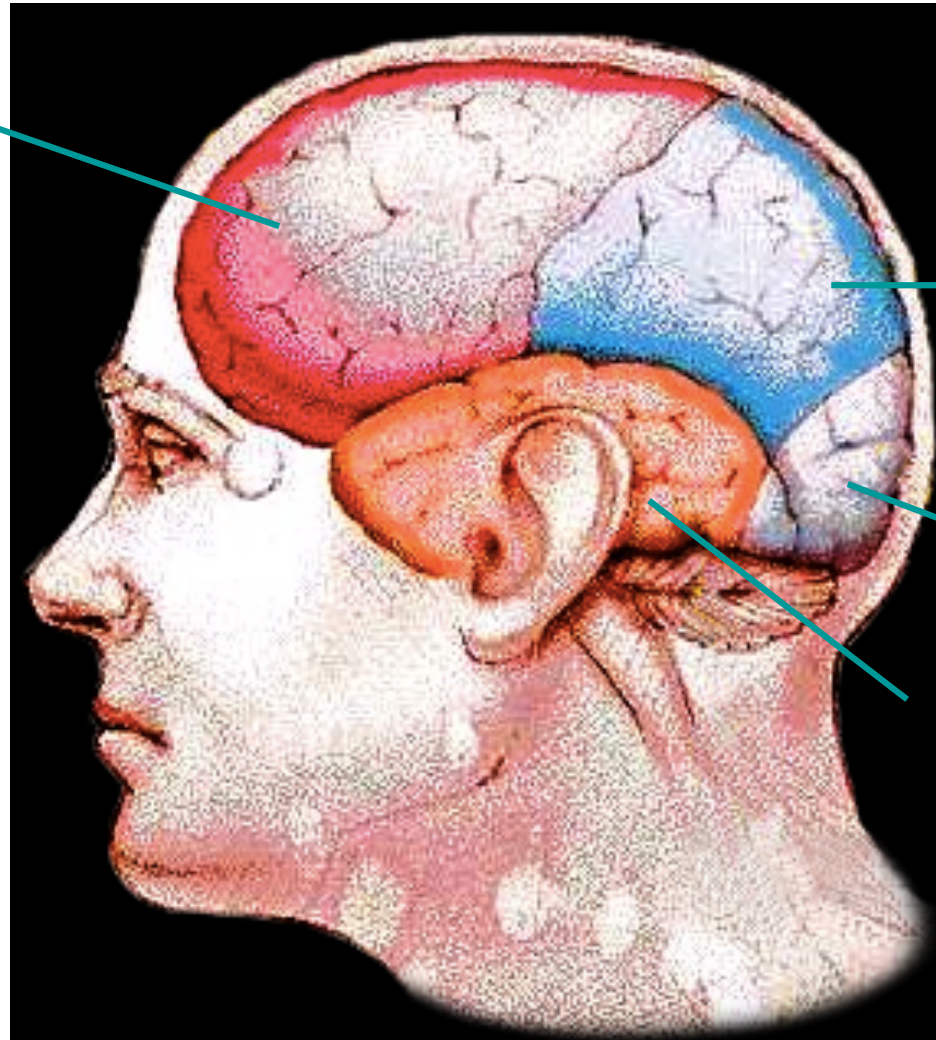

Major Fissures of the Human Brain



Each hemisphere is divided into 4 lobes

Frontal

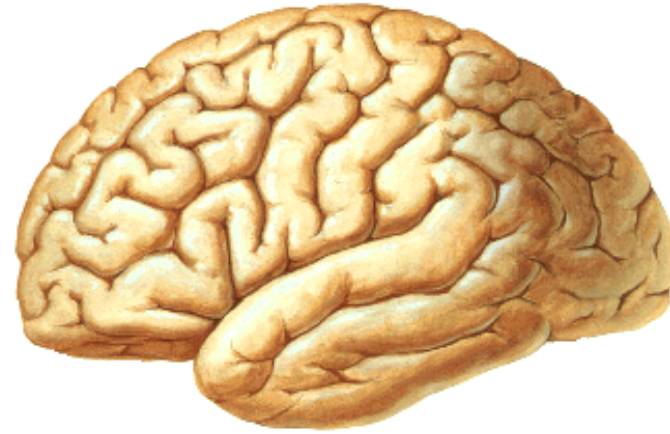


Parietal

Occipital

Temporal

Cerebral Cortex



- **3 types of functional areas:**

1. Motor →

Control voluntary
motor functions

2. Sensory →

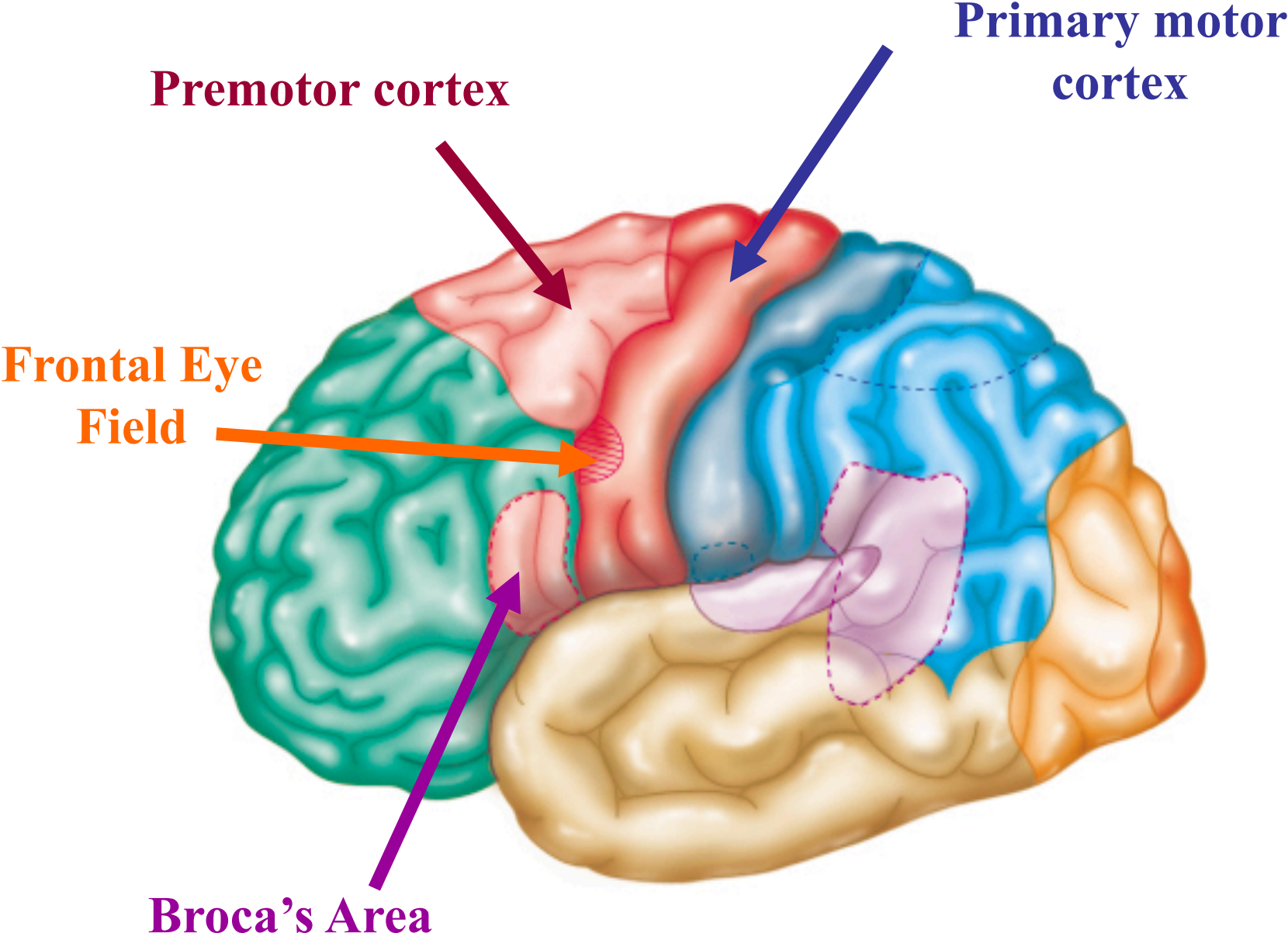
Allow for conscious
recognition of

stimuli

3. Association →

Integration

Cortical Motor Areas



Contralateral Motor Control

- Movements controlled by motor area
- Right hemisphere controls left side of body
- Left hemisphere controls right side
- Motor nerves cross sides in spinal cord

Primary motor cortex

- Voluntary motor control.
- Presents Somatotopy: The entire body is represented spatially

Premotor Cortex

- Involved in learned or patterned skills and in planning movements.

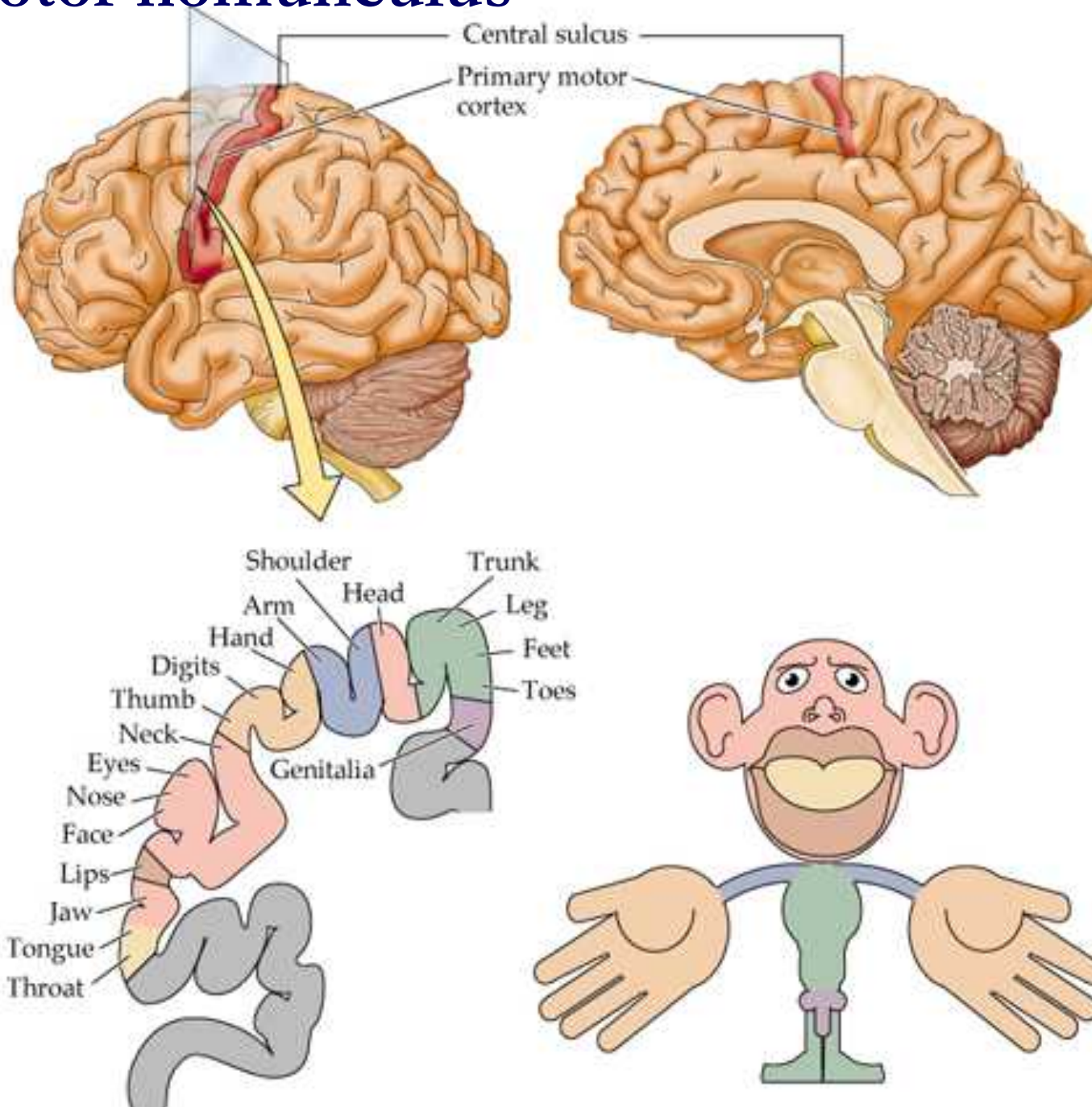
Broca's Area

- Typically found only in the left hemisphere
- Directs muscles of tongue, lips, and throat that are used in speech production.
- Involved in planning speech production

Frontal Eye Field

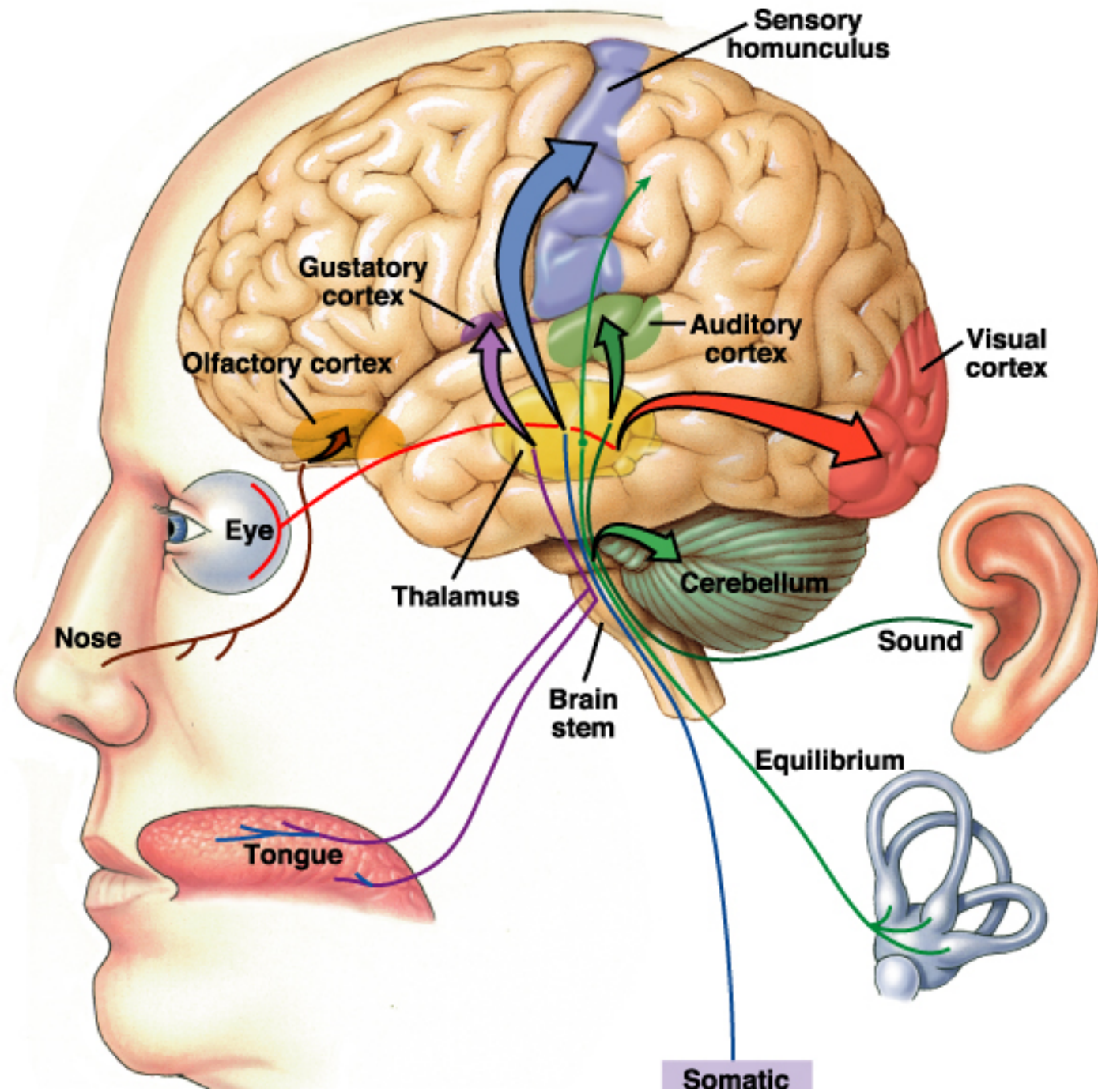
- Controls voluntary eye movements.

The motor homunculus



Sensory Areas

- Found in the parietal, occipital, and temporal lobes.
 1. Primary somatosensory cortex
 2. Somatosensory association cortex
 3. Visual areas
 4. Auditory areas
 5. Olfactory cortex
 6. Gustatory cortex
 7. Vestibular cortex



Sensory Information sent to opposite hemisphere

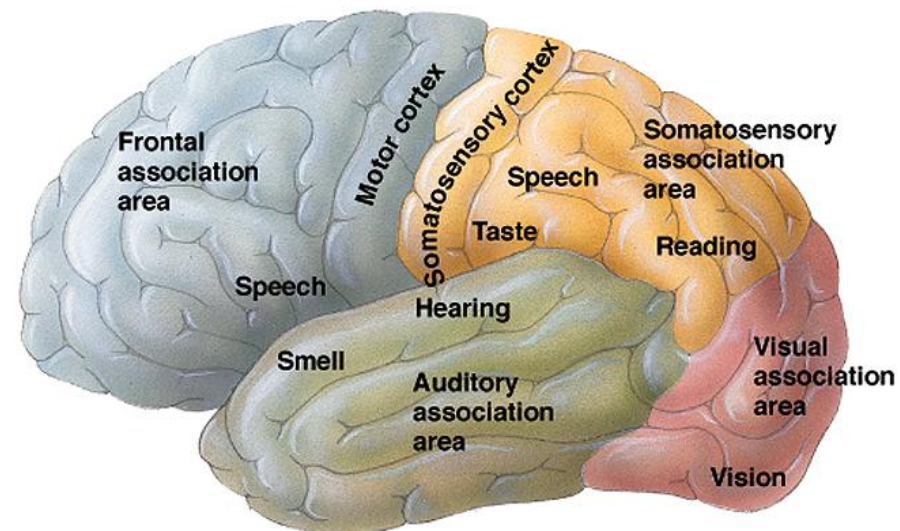
- Principle is Contralateral Organization
- Sensory data crosses over in pathways leading to the cortex
- Visual Crossover
 - left visual field to right hemisphere
 - right field to left
- Other senses similar

Primary Somatosensory Cortex

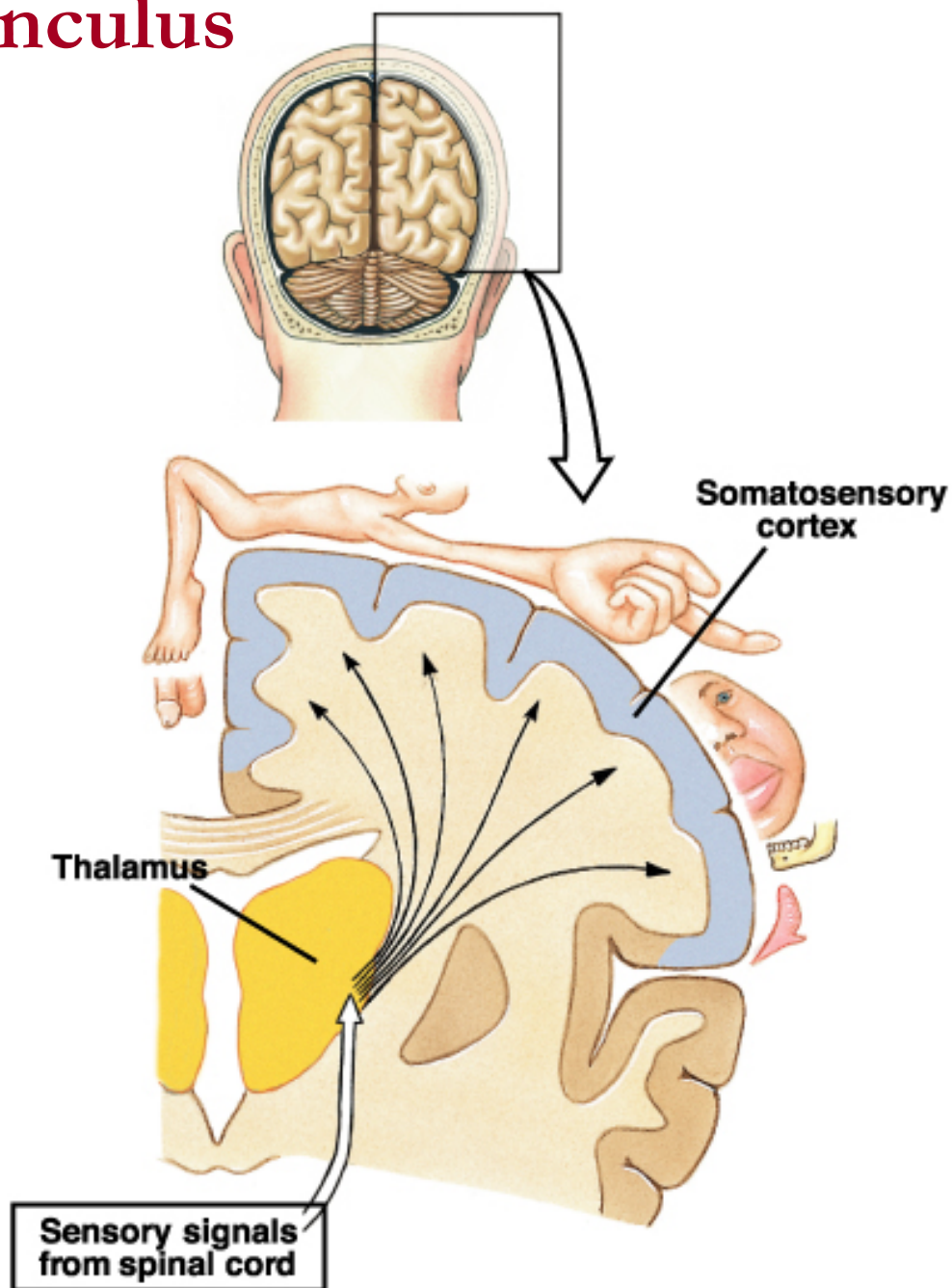
- Receives from sensory neurons in the skin and from joints
- Somatotopy?

Somatosensory Association Cortex

- Posterior to the primary somatosensory cortex
- Analysis of sensory inputs to create a complete comprehension of the object being felt.



The sensory homunculus



Cross section of the right cerebral hemisphere and sensory areas of the cerebral cortex

Visual Areas

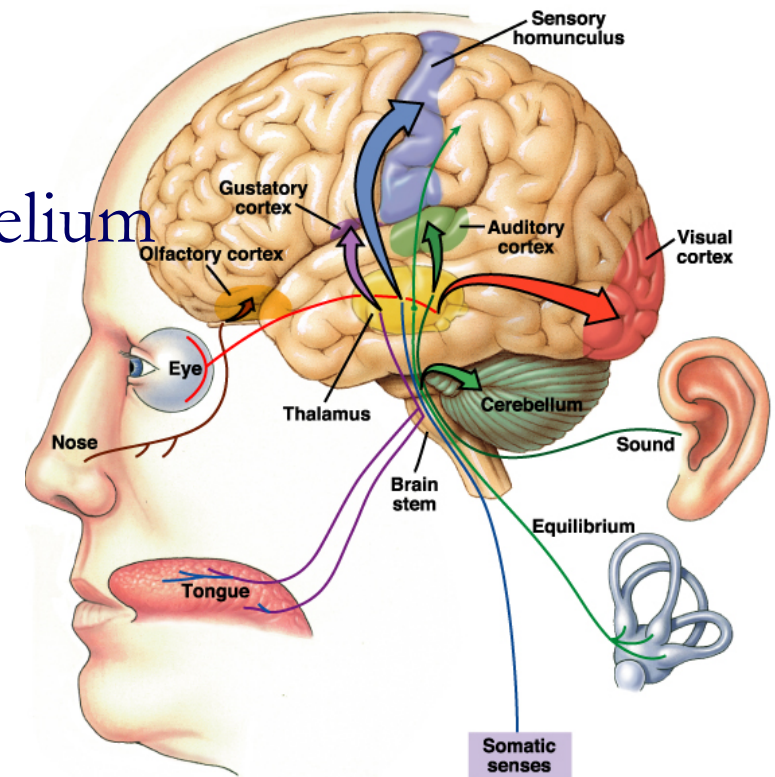
- Primary: sensory input from retina
- Association: object analysis (Shape, Color, Movement)

Auditory Areas

- Primary: sensory input from cochlea
- Association: interpret and remember sounds.

Olfactory Cortex

- Sensory input from olfactory epithelium
- Involved in memory and emotion.

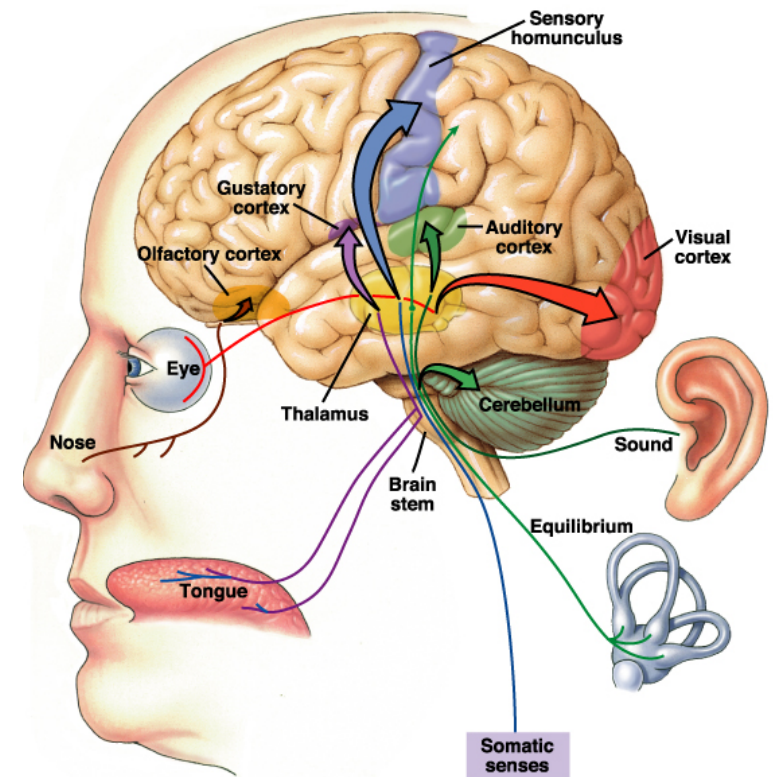


Gustatory cortex

- Sensory input from taste buds
- Involved in taste

Vestibular cortex

- Sensory input from vestibular apparatus
- Involved in balance and equilibrium



Multimodal Association Areas

Receive multiple sensory input from primary and association areas and help make associations between various kinds of sensory info.

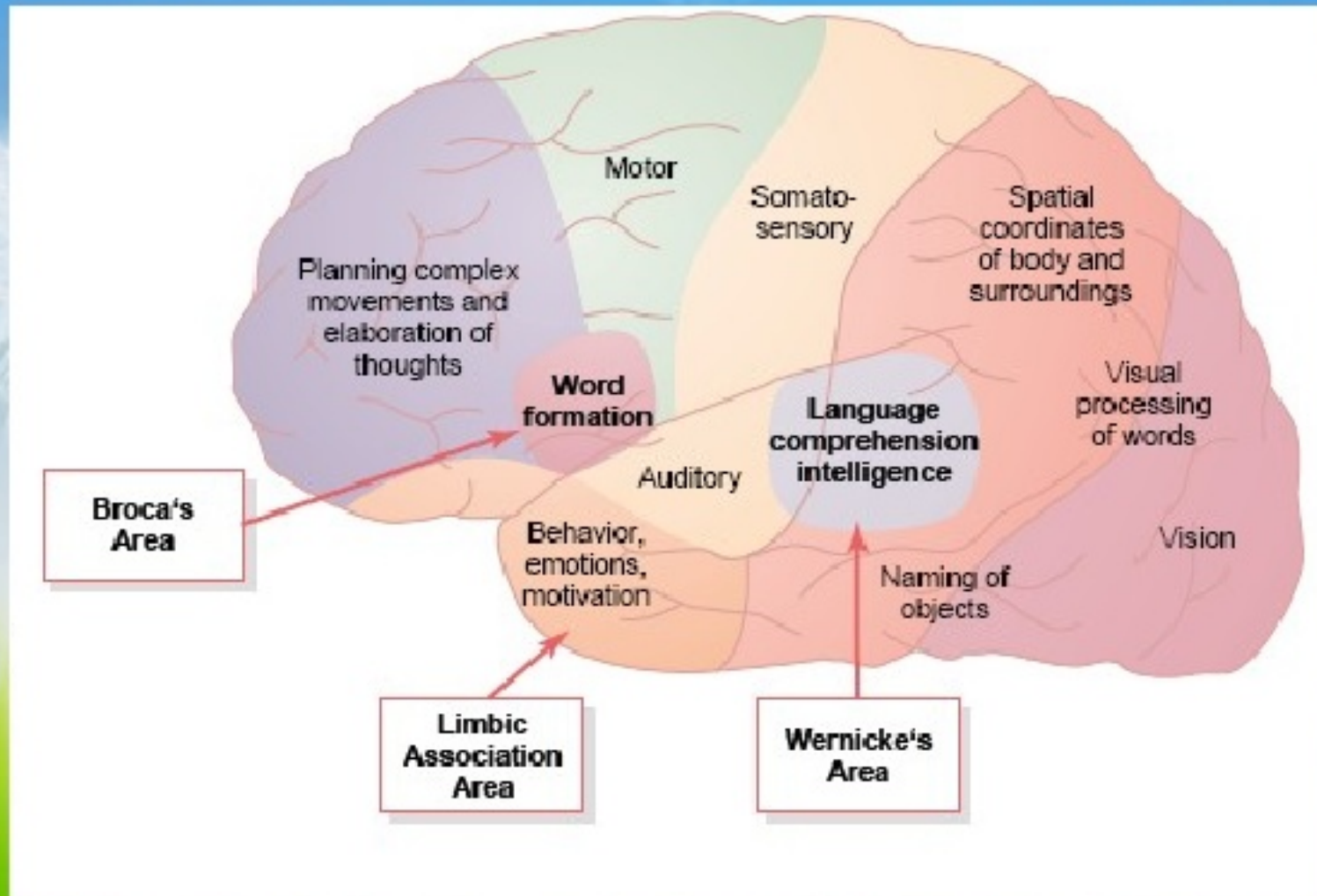
1-Posterior

2- Anterior

3- Limbic

.

Association cortices



The posterior association area

- Visual, auditory and somatosensory association areas
- Spatial awareness of our body.
- **Wernicke's area** that deals with reading, naming things.
- On the right side this area helps us to understand emotional overtones/undertones of speech.

The anterior association area

-The prefrontal cortex.

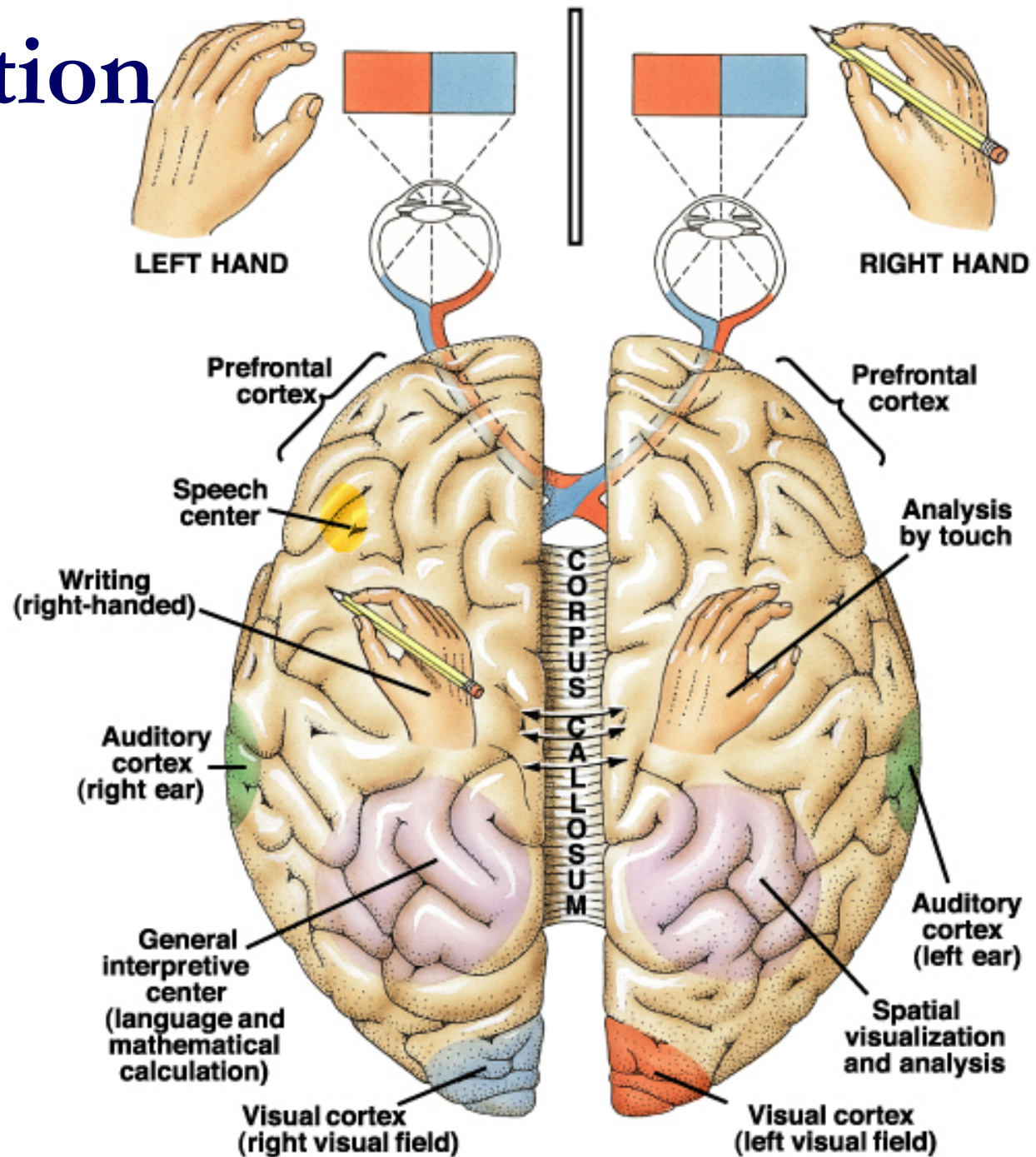
-Thinking and making judgments and understanding social behavior.

The limbic association area

-In the medial side of the frontal lobe.

-Forms memories, processes emotions and guides emotional responses.

Lateralization



Lateralization

- Certain activities are the almost exclusively controlled in one of the 2 hemispheres.
 - The left hemisphere has a more control over language, math, and logic.
 - While the right hemisphere is geared towards musical, artistic and other creative endeavors.

Most individuals with left cerebral dominance are right-handed.

SUBCORTICAL STRUCTURES;

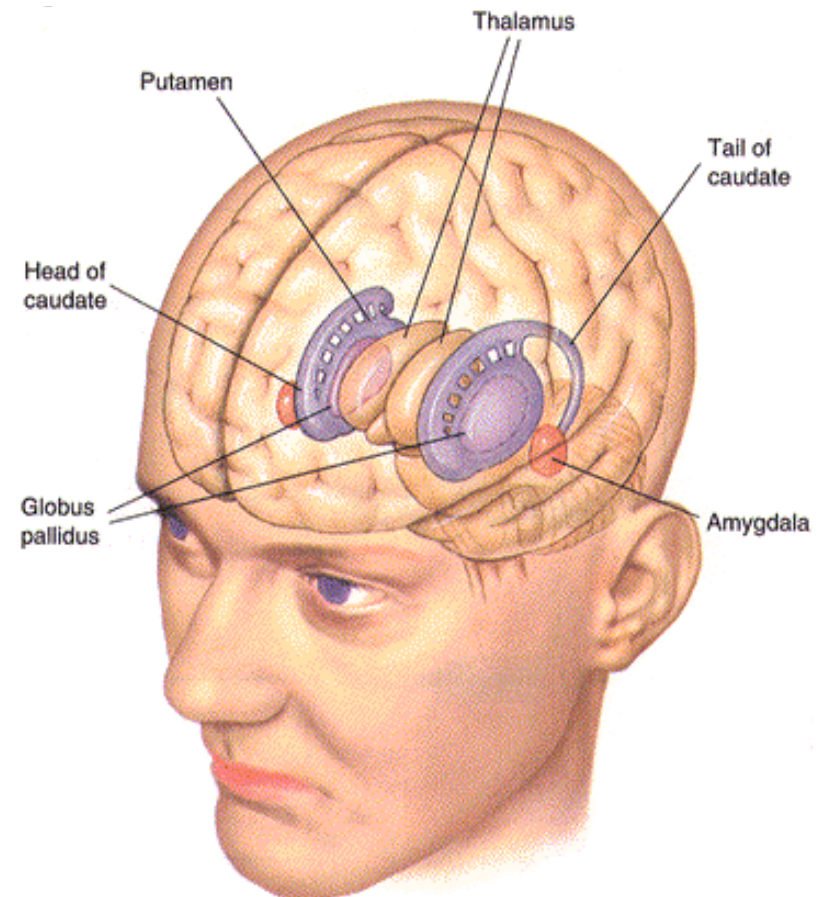
*some structures cannot be seen from the
surface of the brain*

- **BASAL GANGLIA**
- **THALAMUS**
- **HYPOTHALAMUS**
- **LIMBIC SYSTEM**

BASAL GANGLIA

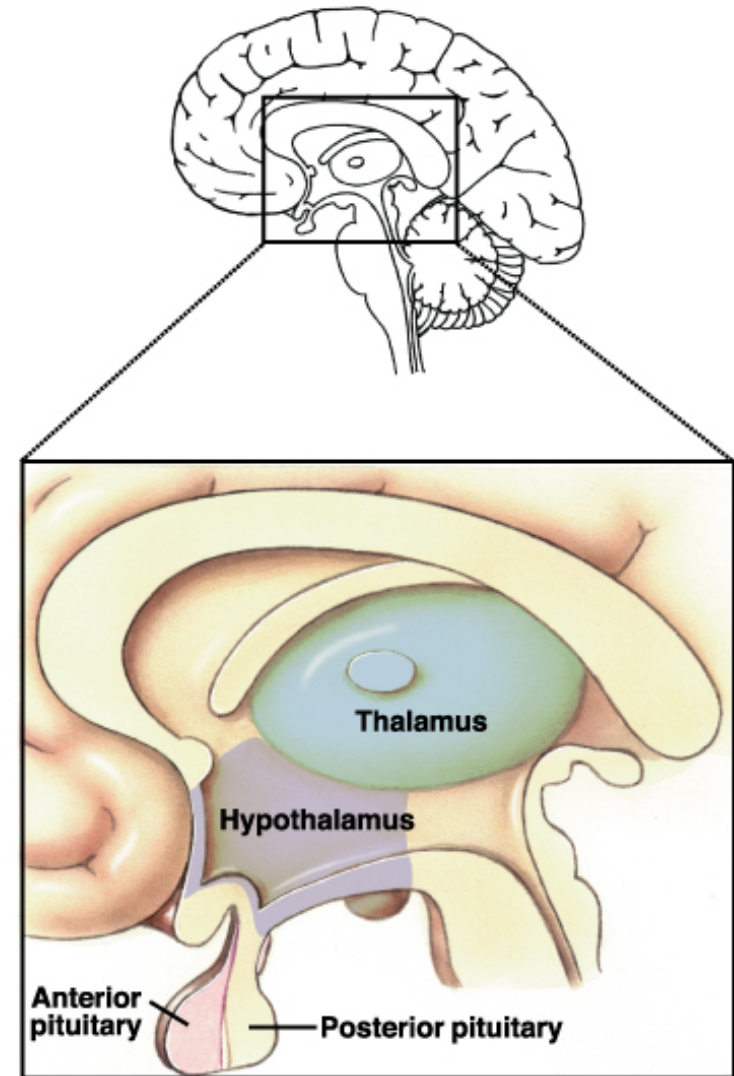
Striatum, Globus Pallidus & “Substantia Nigra”

- **PLAY A COMPLEX ROLE IN THE CONTROL OF MOVEMENT**
- **INHIBIT MUSCLE TONE THROUGHOUT BODY**
- **SUPPRESS USELESS OR UNWANTED PATTERNS OF MOVEMENT**



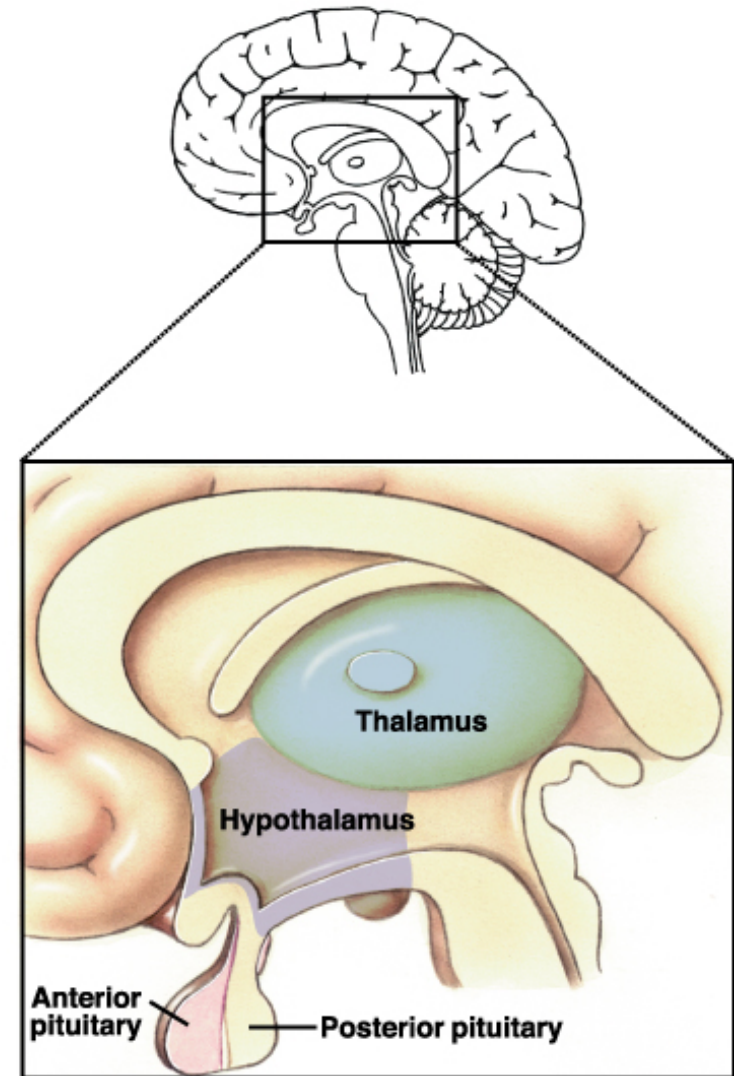
THALAMUS

- RELAY STATION
- SENSORY SWITCHBOARD
- HELP US DIRECT OUR ATTENTION
- FILTERS OUT INSIGNIFICANT SIGNALS



HYPOTHALAMUS

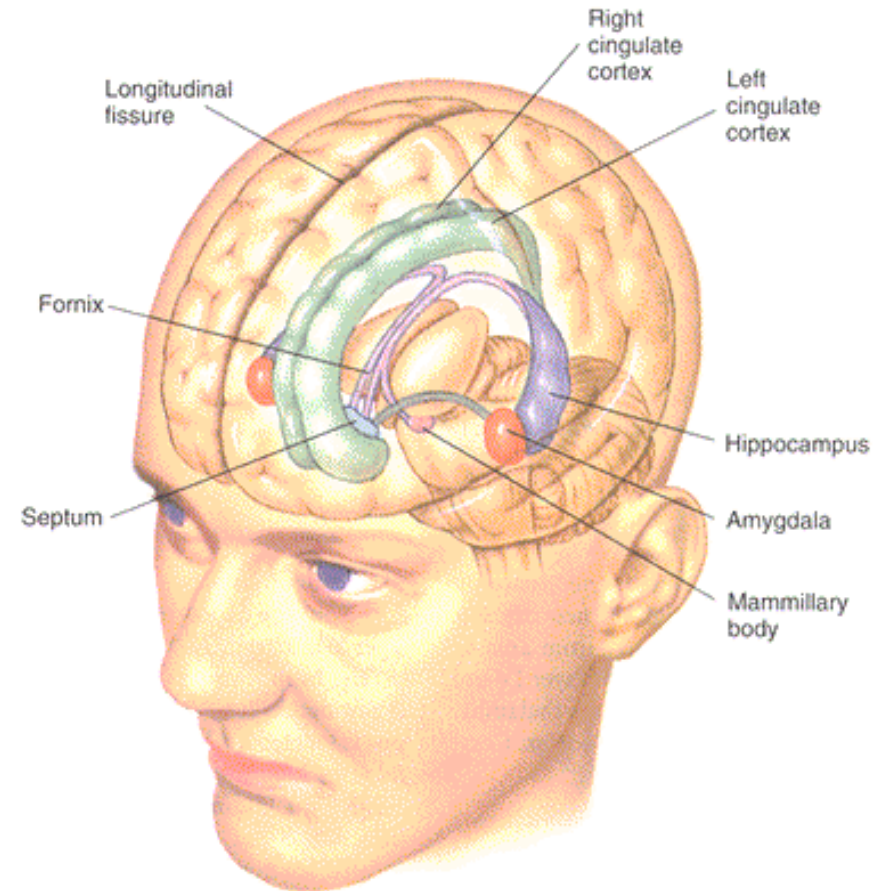
- HOMEOSTATIC FUNCTIONS
- BIOLOGICAL RHYTHMS
- THIRST AND URINE OUTPUT
- FOOD INTAKE
- HORMONE SECRETION
- BODY TEMPERATURE
- AUTONOMIC NERVOUS SYSTEM'S COORDINATING CENTER



LIMBIC SYSTEM

Hippocampus, Amygdala & Cingulate Cortex

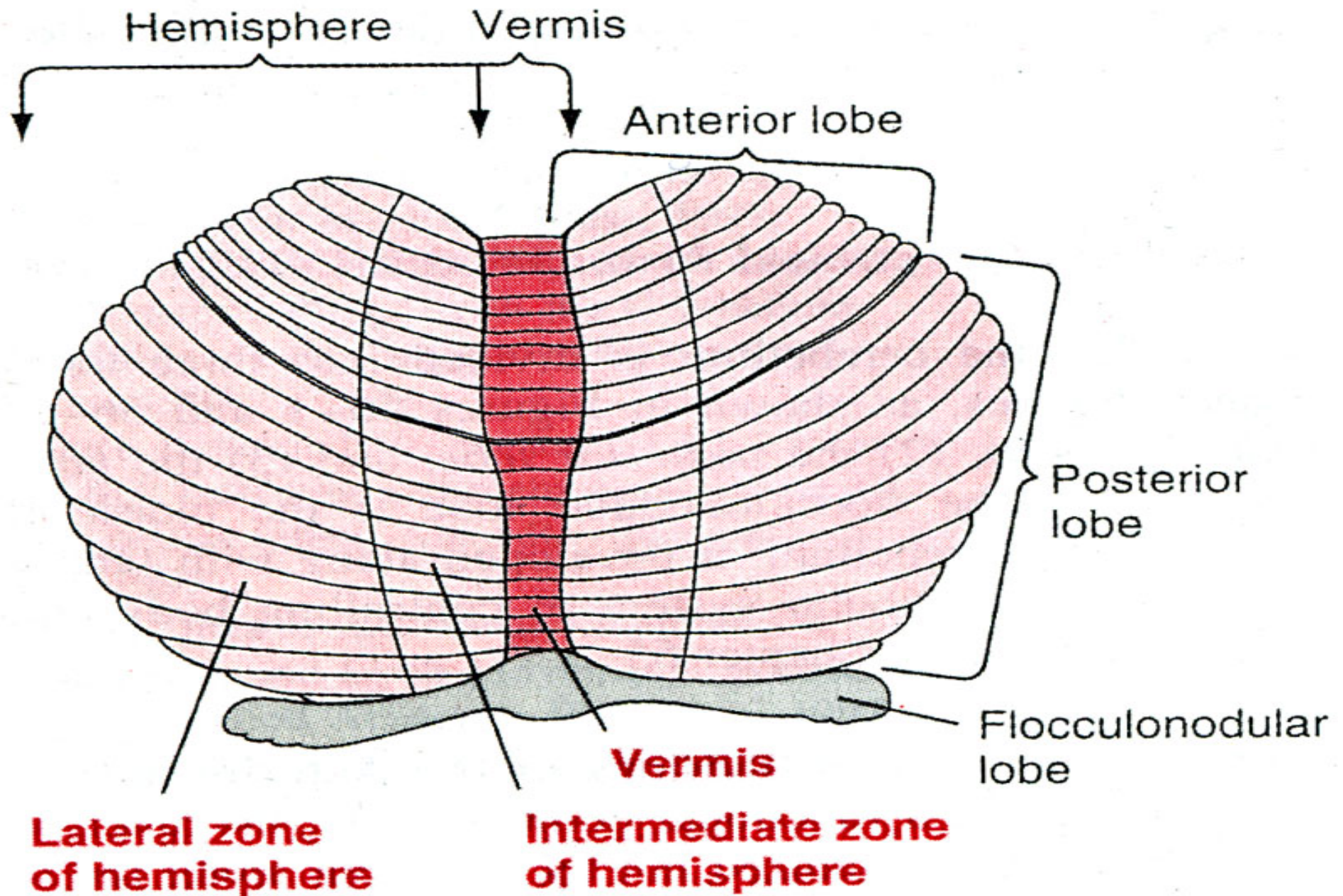
- **EMOTIONS**
- **BASIC SURVIVAL**
- **BEHAVIOR**
- **MOTIVATION**
- **LEARNING**
- **MEMORY**



Medulla Centers

- **Cardiovascular control center** – adjusts force and rate of heart contraction
- **Respiratory centers** – control rate and depth of breathing
- **Additional centers** – regulate vomiting , hiccupping , swallowing , coughing , and sneezing.

The cerebellum and its motor functions



Functional Divisions and roles of the cerebellum

- Vestibulocerebellum in the flocculonodular lobe

Balance and body equilibrium

- Spinocerebellum in the vermis & intermediate zone

Rectify voluntary movement




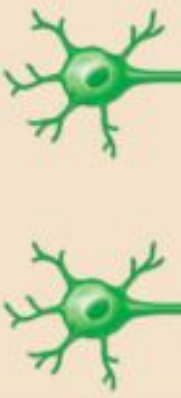
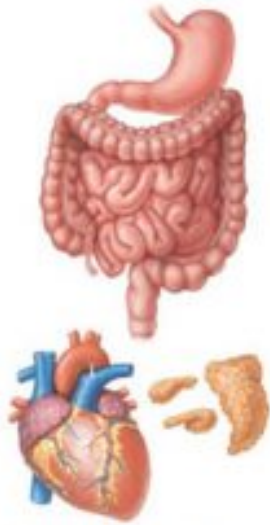

Smooth coordination of **decided patterned movements**

- Cerebrocerebellum in the lateral zone

Plan voluntary movement

The Autonomic nervous system

Comparison of Autonomic and Somatic Motor Systems

Cell bodies in central nervous system		Peripheral nervous system	Neurotransmitter at effector	Effector organs	Effect
SOMATIC NERVOUS SYSTEM		Single neuron from CNS to effector organs Heavily myelinated axon	ACh 	 Skeletal muscle	+ Stimulatory
AUTONOMIC NERVOUS SYSTEM		Two-neuron chain from CNS to effector organs		 Smooth muscle (e.g., in gut), glands, cardiac muscle	+ - Stimulatory or inhibitory, depending on neurotransmitter and receptors on effector organs
		SYMPATHETIC	Lightly myelinated preganglionic axons Ganglion Unmyelinated postganglionic axon Adrenal medulla Blood vessel Epinephrine and norepinephrine		
PARASYMPATHETIC	Lightly myelinated preganglionic axon Ganglion Unmyelinated postganglionic axon	ACh 			

 Acetylcholine (ACh)  Norepinephrine (NE)

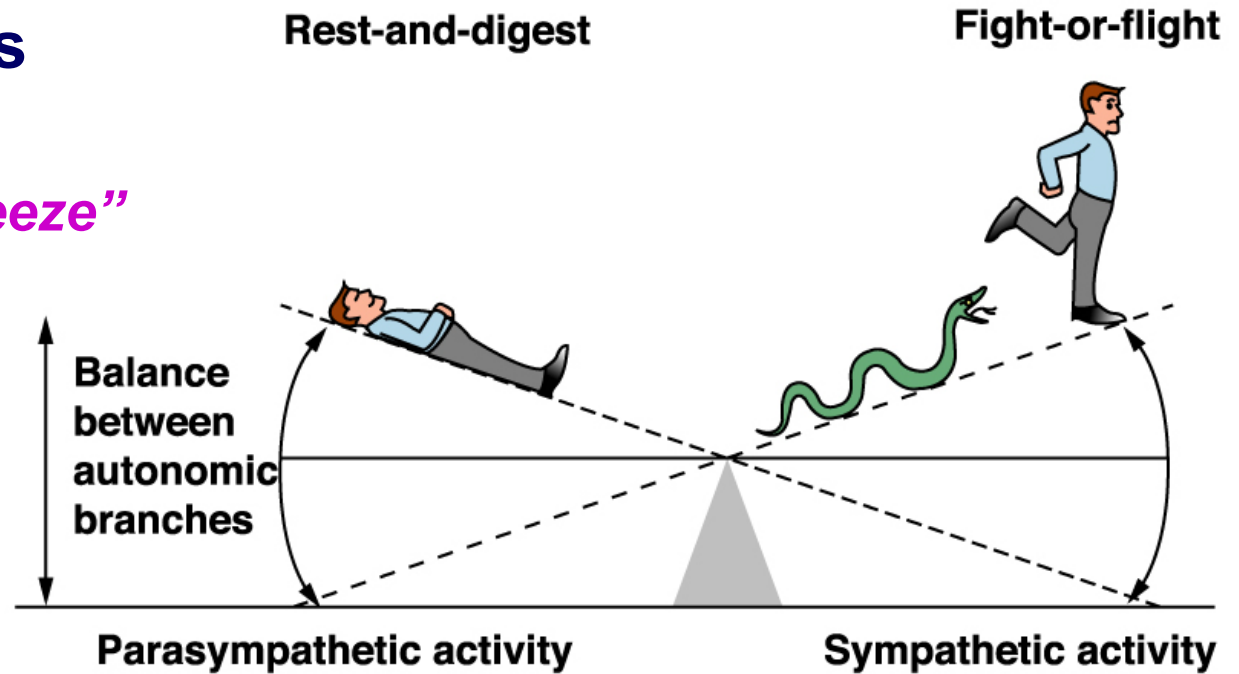
PNS: Autonomic System (ANS)

➤ Sympathetic Nervous System

- *“Fight or Flight or Freeze”*

➤ Parasympathetic Nervous System

- *“Rest and Digest”*

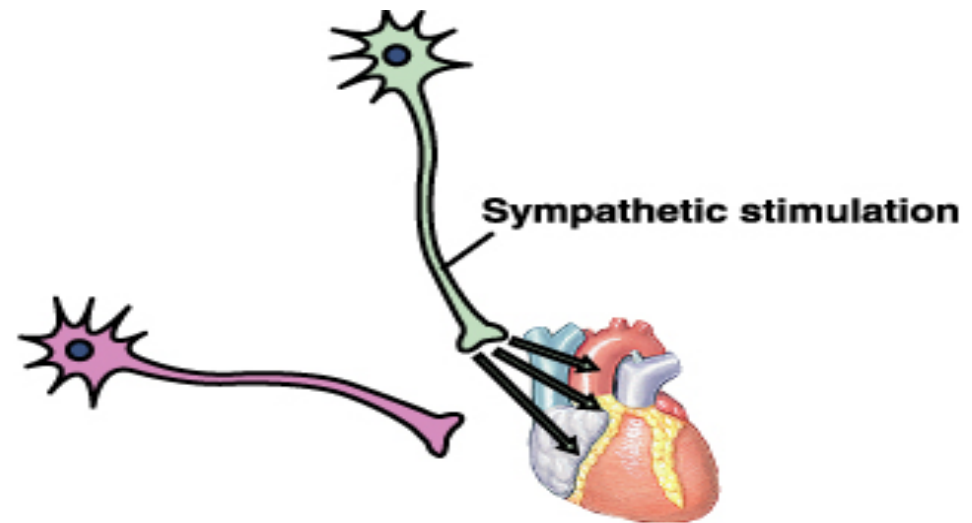


These 2 systems are antagonistic:

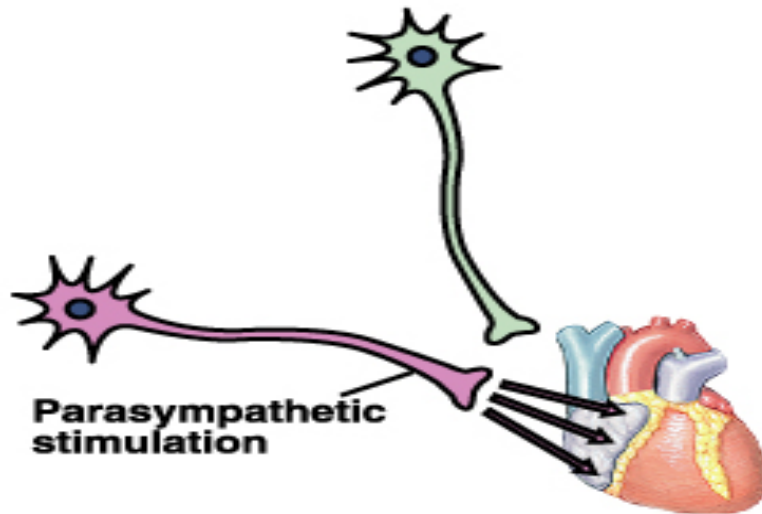
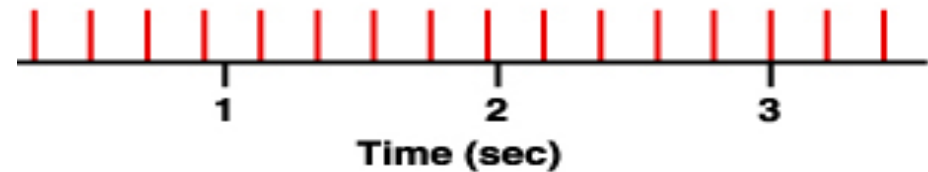
Typically, we balance these 2 to keep ourselves in a state of dynamic balance

Antagonistic Control

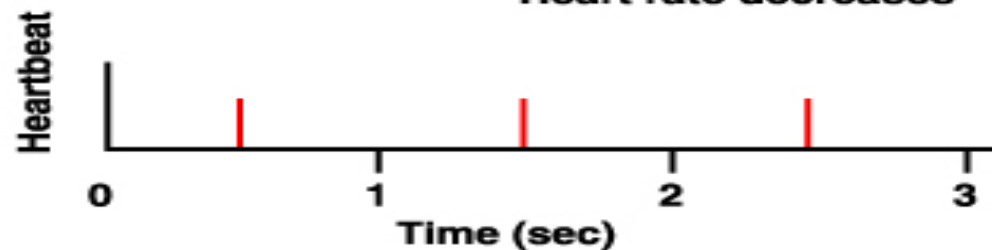
- Most internal organs are innervated by both branches



Heart rate increases



Heart rate decreases



Ex: heart rate.

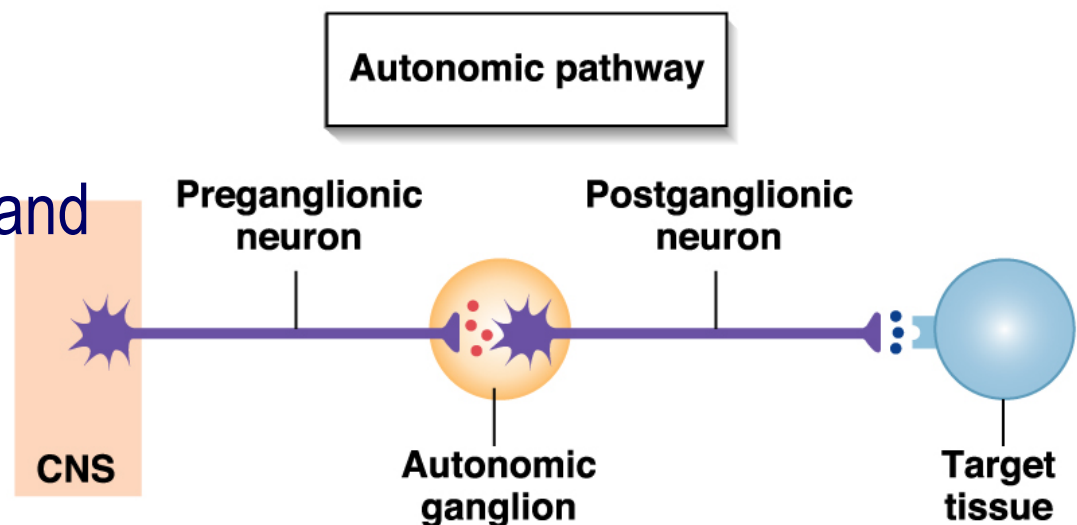
↑ sympathetic stimulation causes HR to increase

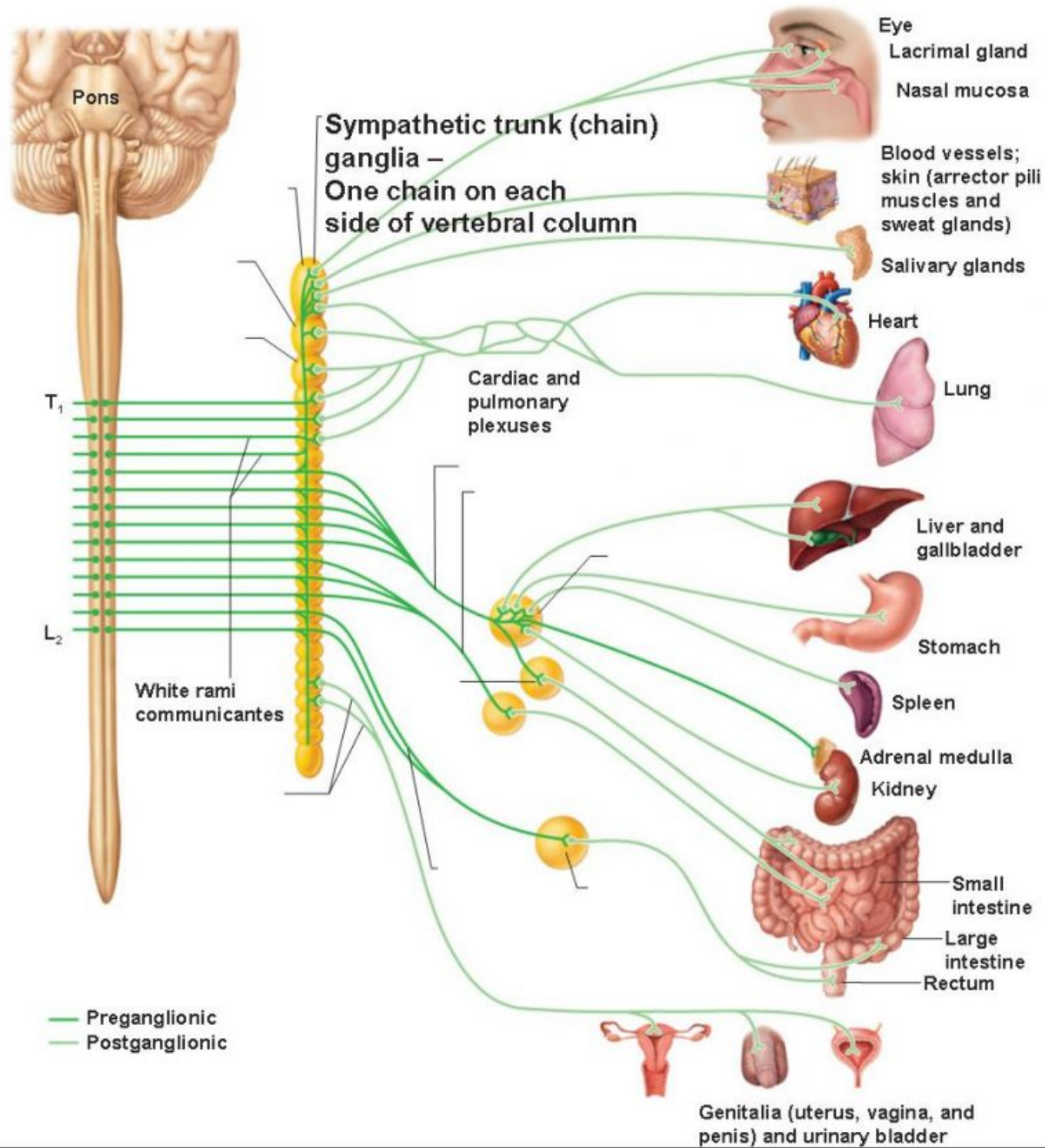
↑ parasympathetic stimulation causes HR to decrease

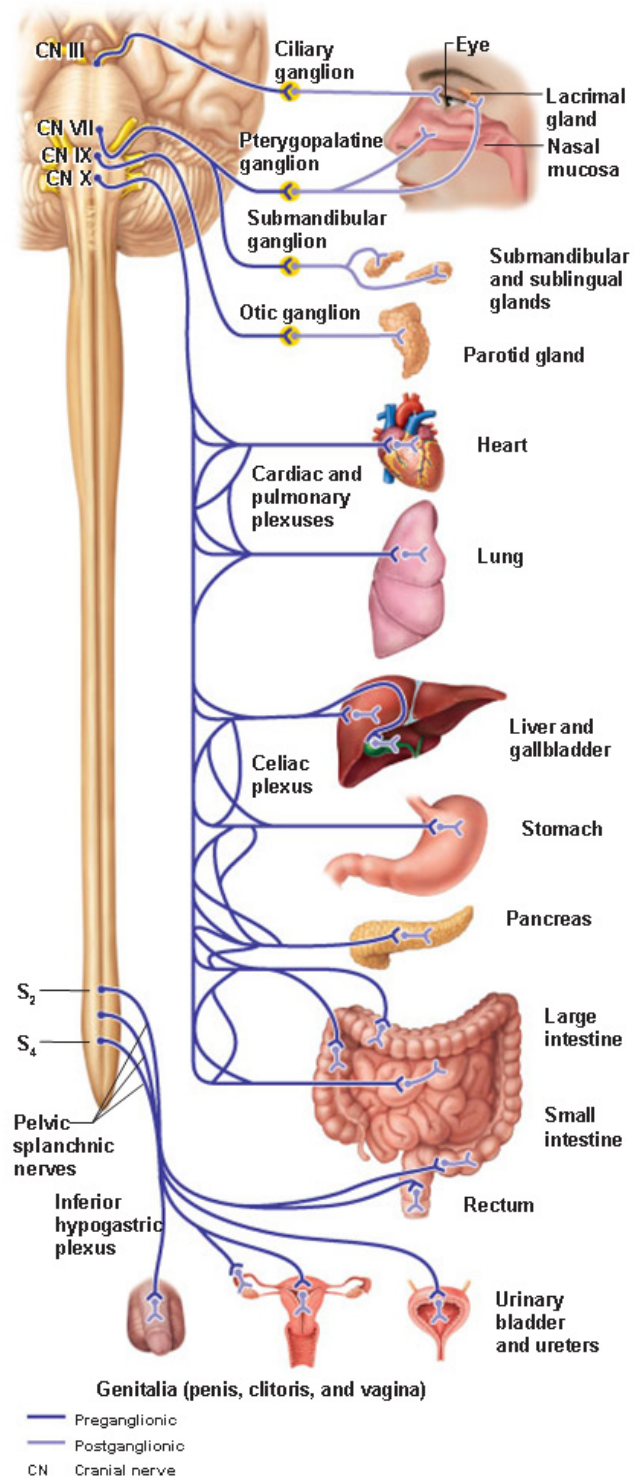
2 neurons in series.

- They synapse in an autonomic ganglion
- The 1st neuron is the preganglionic neuron,
 - Cell body in CNS, myelinated, and projects to the autonomic ganglion.
- The 2nd neuron is the postganglionic neuron.
 - Cell body in autonomic ganglion, unmyelinated, and projects to the effector.

ANS Structure







Sympathetic vs. Parasympathetic

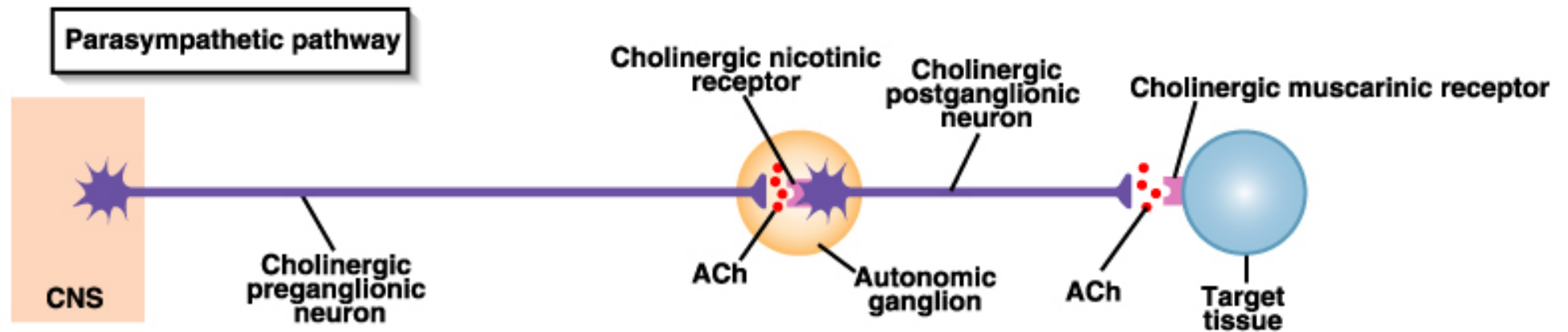
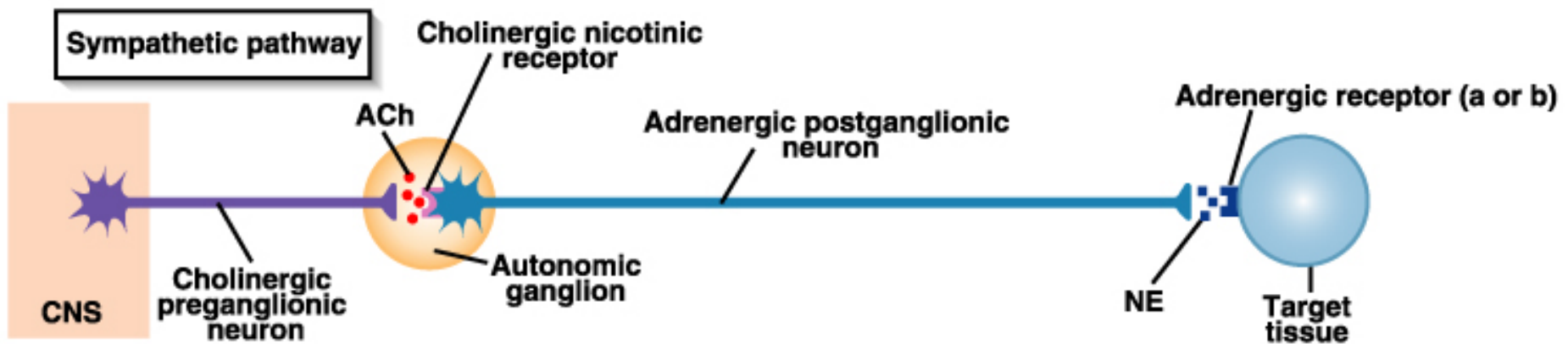
Structural Differences:

	<i>Symp</i>	<i>Parasymp</i>
<i>Point of CNS Origin</i>	T1 → L2 (thoracolumbar)	Brainstem, S2 → S4 (craniosacral)
<i>Site of Peripheral Ganglia</i>	Paravertebral	On or near target tissue
<i>Length of preganglionic fiber</i>	Short	Long
<i>Length of postganglionic fiber</i>	Long	Short

Sympathetic vs. Parasympathetic

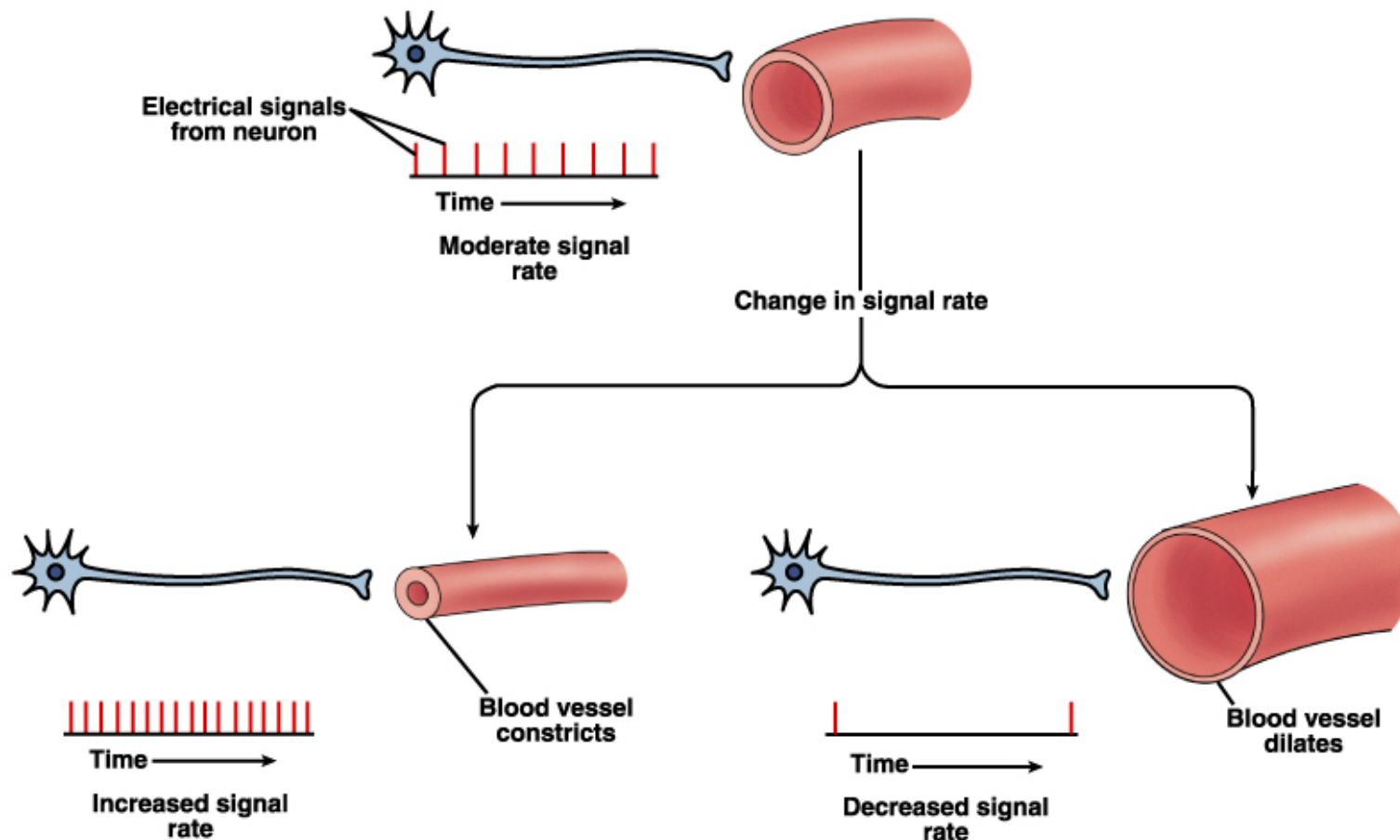
Receptor/NT Differences:

	<i>Symp</i>	<i>Parasymp.</i>
<i>NT at Target Synapse</i>	Norepinephrine (adrenergic neurons)	Acetylcholine (cholinergic neurons)
<i>Type of NT Receptors at Target Synapse</i>	Alpha and Beta (α and β)	Muscarinic
<i>NT at Ganglion</i>	Acetylcholine	Acetylcholine
<i>Receptor at Ganglion</i>	Nicotinic	Nicotinic



Exception to the dual innervation rule:

Sweat glands and blood vessel smooth muscle are only innervated by sympathetic division.



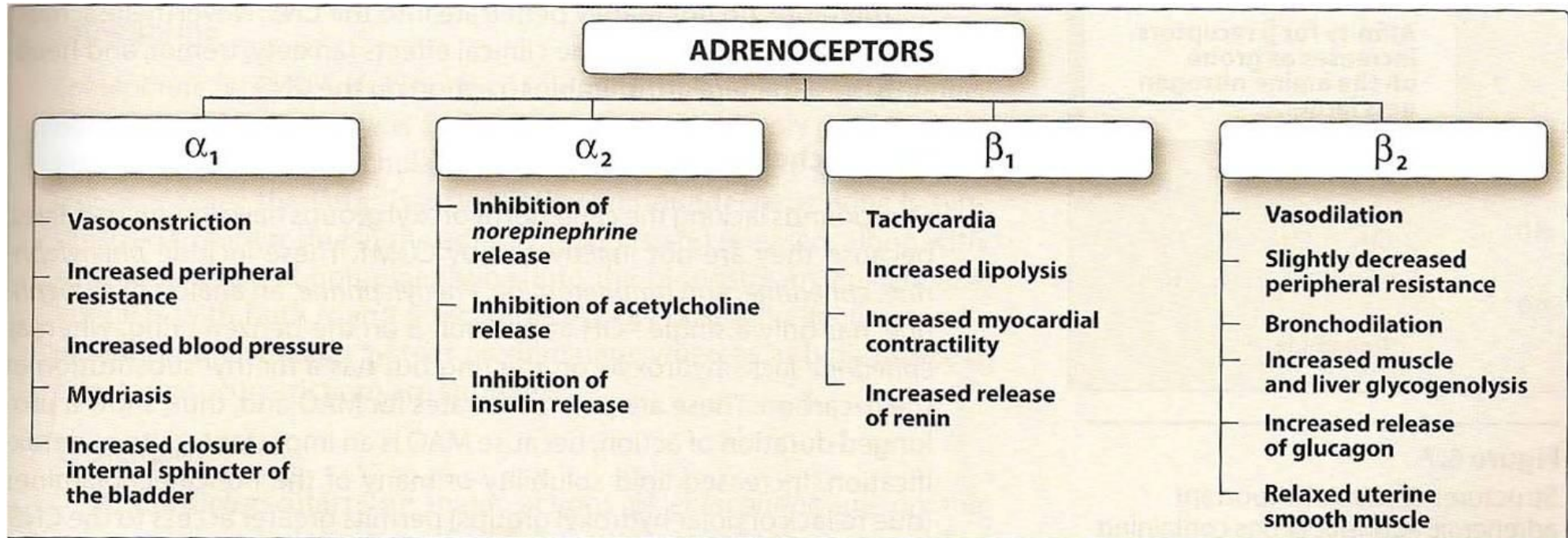
Sympathetic vs. Parasympathetic *Effects*

<i>Target Organ</i>	<i>Parasympathetic Effects</i>	<i>Sympathetic Effects</i>
<u>Eye (Iris)</u>	Stimulates constrictor muscles. Pupil constriction.	Stimulates dilator muscles. Pupil dilates.
<u>Eye (Ciliary muscle)</u>	Stimulates. Lens accommodates – allows for close vision.	No innervation.
<u>Salivary Glands</u>	Watery secretion.	Mucous secretion.
<u>Sweat Glands</u>	No innervation.	Stimulates sweating in large amounts. (Cholinergic)
<u>Gallbladder</u>	Stimulates smooth muscle to contract and expel bile.	Inhibits gallbladder smooth muscle.

<i>Target Organ</i>	<i>Parasympathetic Effects</i>	<i>Sympathetic Effects</i>
<u>Cardiac Muscle</u>	Decreases HR.	Increases HR and force of contraction.
<u>Coronary Blood Vessels</u>	Constricts.	Dilates
<u>Urinary Bladder; Urethra</u>	Contracts bladder smooth muscle; relaxes urethral sphincter.	Relaxes bladder smooth muscle; contracts urethral sphincter.
<u>Lungs</u>	Contracts bronchiole (small air passage) smooth muscle.	Dilates bronchioles.
<u>Digestive Organs</u>	Increases peristalsis and enzyme/mucus secretion.	Decreases glandular and muscular activity.

<i>Target Organ</i>	<i>Parasympathetic Effects</i>	<i>Sympathetic Effects</i>
<u>Kidney</u>	No innervation.	Releases the enzyme renin which acts to increase BP.
<u>Cellular Metabolism</u>	No effect.	Increases metabolic rate.
<u>Endocrine Pancreas</u>	Stimulates insulin secretion.	Inhibits insulin secretion.
<u>Blood Vessels</u>	Little effect.	Constricts most blood vessels and increases BP. Exception – dilates blood vessels serving skeletal muscle fibers (cholinergic).
<u>Adipose Tissue</u>	No effect.	Stimulates fat breakdown.

Adrenergic receptors



Muscarinic receptors

Location and Function of Muscarinic Receptors

M₁

AUTONOMIC GANGLIA:
depolarization, alters
autonomic nerve messaging

GASTRIC GLANDS:
histamine release,
acid secretion

BRAIN:
increase memory, attention,
emotional responses

M₂

HEART:
reduces heart rate,
slows AV node conduction,
reduces force of contraction

M₃

GI TRACT & GALLBLADDER:
smooth muscle contraction

PUPILS:
regulates pupil constriction

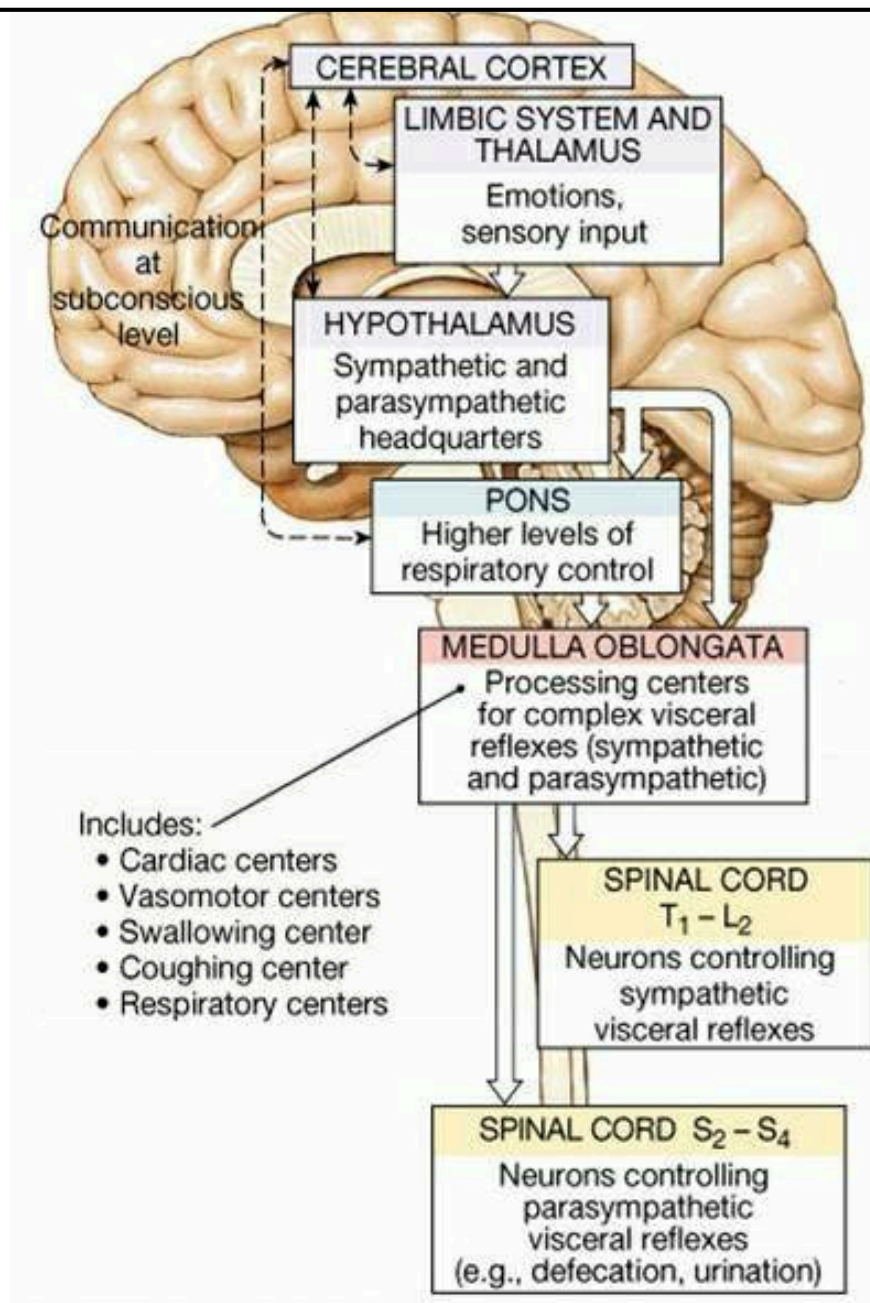
GLANDS:
promotes eye, mouth, sinus,
lung and skin lubrication

BLOOD VESSELS:
increases vasodilation

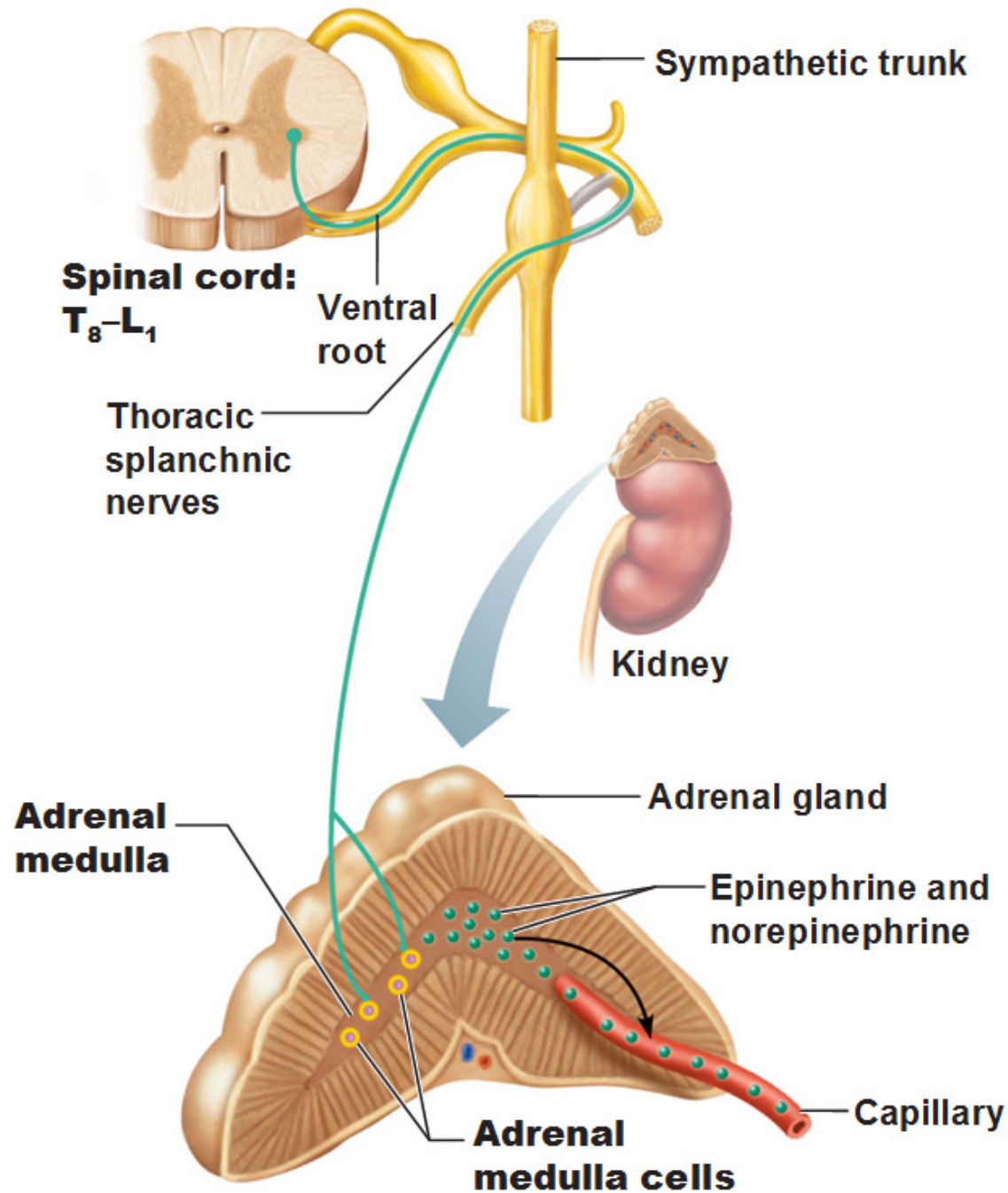
• How Does the Brain Control the ANS?

- The hypothalamus is the Boss:
 - Controls both parasympathetic and sympathetic functions
 - Vital centers in the pons and medulla (cardiovascular centers, respiratory centers)
 - The connection of the limbic system to the hypothalamus mediates our “flight or flight or freeze” response to emotional situations.
 - The relationship between the hypothalamus and the amygdala allow us to respond to fear.

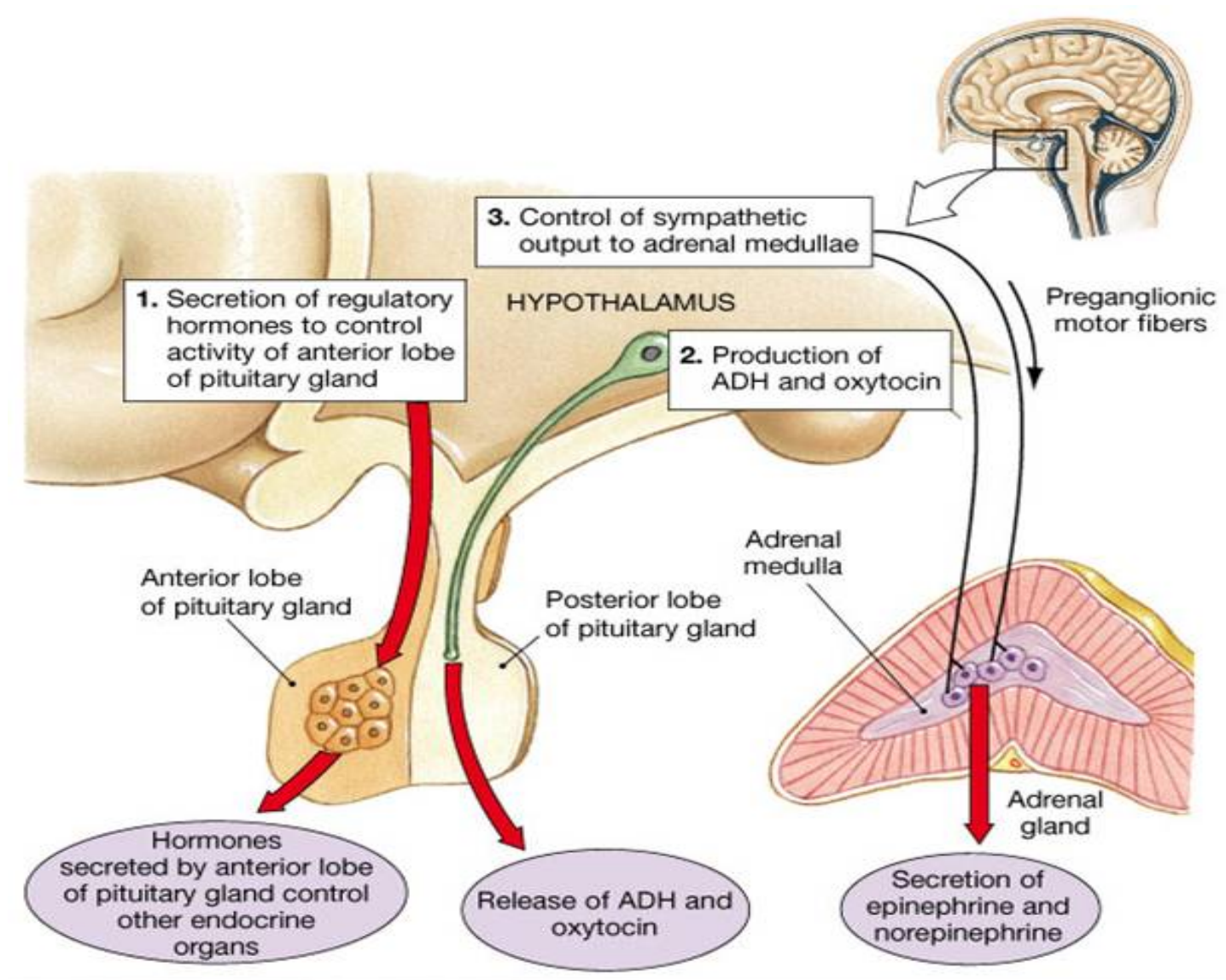
• How Does the Brain Control the ANS?



The Adrenal Medulla of the Adrenal Gland



Relationship between Hypothalamus and Adrenal Medulla



Stress and Adrenal Medulla

